


Periprosthetic knee infection due to *Pasteurella multocida*: the cat was guilty!



Dupieux C^{1,2}, Mouton T^{2,3}, Salord H^{1,2}, Roure-Sobas C^{1,2}, Chidiac C^{2,4}, Tigaud S^{1,2}, Ferry T^{2,4}, Lustig S^{2,3}, Laurent F^{1,2}.

¹ Bactériologie, Hôpital de la Croix-Rousse – ² Centre de Référence des Infections Ostéo-Articulaires Complexes, CRIOA de Lyon – ³ Chirurgie orthopédique, Hôpital de la Croix-Rousse – ⁴ Maladies Infectieuses et Tropicales, Hôpital de la Croix-Rousse, Hospices Civils de Lyon, Lyon, France

Introduction and Objectives

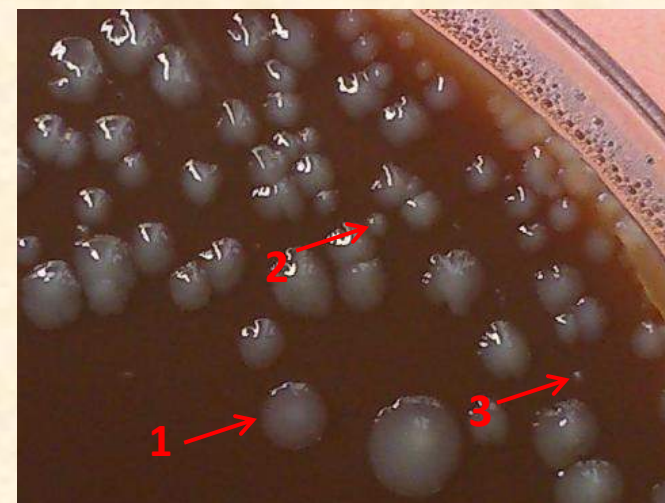
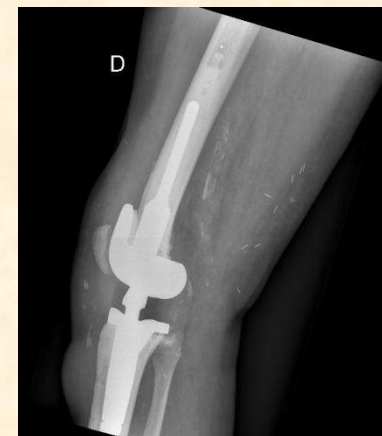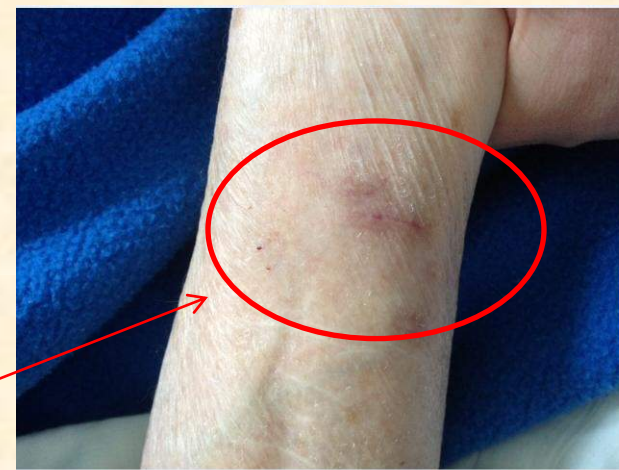Periprosthetic infections are most commonly due to staphylococci or less often to streptococci or *Enterobacteriaceae*. Here, we present an unfrequent case of prosthetic knee joint infection due to *Pasteurella multocida* after a cat scratch.

Case: initial presentation

A **76-year-old woman** with a recent history of allergy to penicillins and cephalosporins presented with a **total knee arthroplasty infection** consisting of an acute septic arthritis associated with an abscess of the anteromedial side of the right knee. Prosthesis had been replaced 10 months earlier for recurrent *Streptococcus* infection. Patient interview revealed that she had been **scratched by her cat** over the forearms two weeks before the symptoms onset.

Cytological analysis of the synovial fluid indicated a bacterial infection (purulent fluid, leukocyte count of 80.10⁹/L with 99% neutrophils). Cultures were positive for *Pasteurella multocida* with three distinct colony morphotypes. Two were characterized by punctiform and slow-growing colonies, evocative of Small Colony Variants (SCVs). The last morphotype showed slow growing even when iterative subcultures.

Antibiotic susceptibility testing revealed that all three morphotypes were penicillinase negative and susceptible to beta-lactams (amoxicillin, amoxicillin/clavulanate, cefalotin, cefotaxim), gentamicin, erythromycin, levofloxacin, and tetracyclin. Morphotypes 1 and 2 were resistant to lincomycin whereas morphotype 3 (SCV) appeared susceptible. Morphotype 3 had higher inhibition zone diameters than the two other morphotypes for all antibiotics.



After 48h incubation at 37°C, 3 morphotypes of *Pasteurella multocida*: classic (1), SCV visible in 24h (2), SCV visible only after 48h (3).

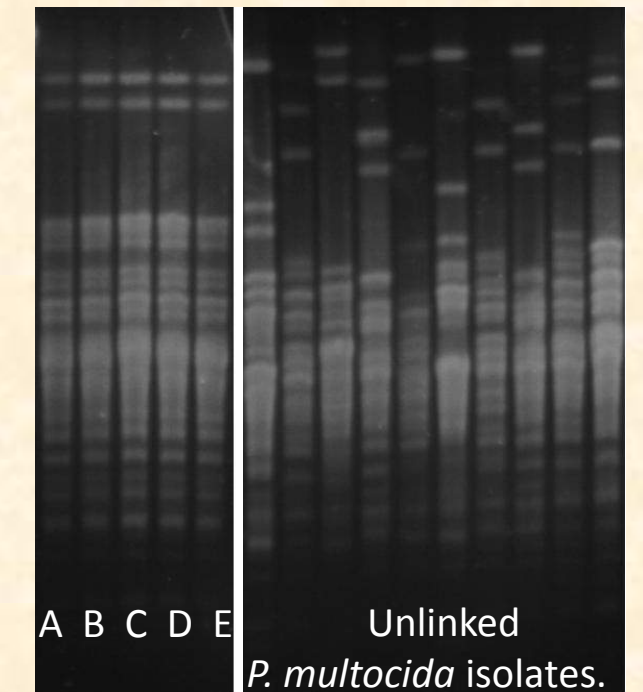
Treatment and evolution

After arthrotomy and irrigation, the patient was treated with **ertapenem** (2g/day, IV) because of the history of allergies. An iterative arthrotomy and irrigation with a flap coverage was necessary one month later due to a pretibial skin damage. No bacteria was isolated in culture at that time. Evolution was initially favorable after three months of treatment but **recurrence** was recently diagnosed 7 months after the initial infection with isolation of *P. multocida* from osteoarticular samples. Isolate remained susceptible to ertapenem. Prosthesis was explanted then patient treated with **tigecyclin** (100mg/day, IV) and **ofloxacin** (400mg/day, per os). Due to a pancreatitis, tigecyclin was stopped two months later. Reimplantation of knee arthrodesis prosthesis occurred two weeks later, followed by a one-month treatment with vancomycin (1.5g/day, IV) and ofloxacin (400mg/day, per os). As all bone samples were sterile at the time of reimplantation, treatment was continued with **doxycycline** (200mg/day, per os) and **ofloxacin** (400mg/day, per os) (still on course). Evolution is currently favorable.

Association between infection and cat's scratch

A mouth swab screening of the patient's cat was performed few days after the initial episode and allowed the culture of a strain of *Pasteurella multocida* without SCVs. Cat's strain had the same antibiotic susceptibility profile than the patient's strain morphotype 1. Comparison of cat's and patient's strains (morphotypes 1-3 including SCVs colonies) using Pulse-Field Gel Electrophoresis (PFGE) with *SmaI* enzyme showed that all the profiles (patient and cat) were identical and that they were different from ten epidemiologically unlinked strains of *P. multocida* collected in our laboratory.

This confirms the presence of **several variants of a same strain in the patient's osteoarticular samples** and the **hypothesis of hematogen transmission related to the scratch**.



PFGE patterns obtained with *SmaI* enzyme. A: cat's strain; B, C, D: patient's initial strain (morphotypes 1, 2, 3); E: relapse strain.

Conclusion

Pasteurella multocida is a rare cause of prosthetic joint infection. Multiple treatment options for this infection have been proposed in the literature and there is no consensus. The few published cases systematically found cat or dog contact and have never described SCVs. Bites and scratches must not be neglected among patients with prosthetic joint since they are potential sources of severe and difficult-to-treat infections.