

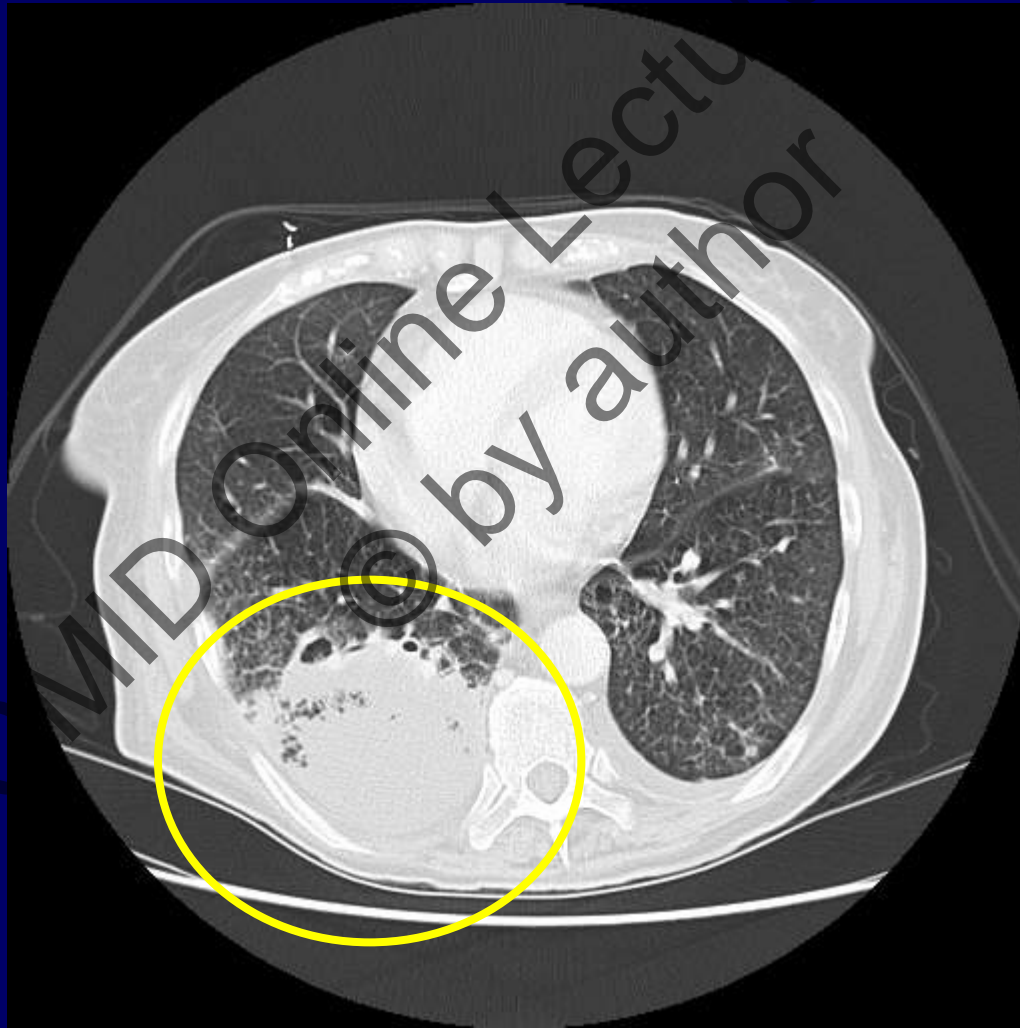
Persistently positive
galactomannan

ESCMID Online Lecture Library
© by author

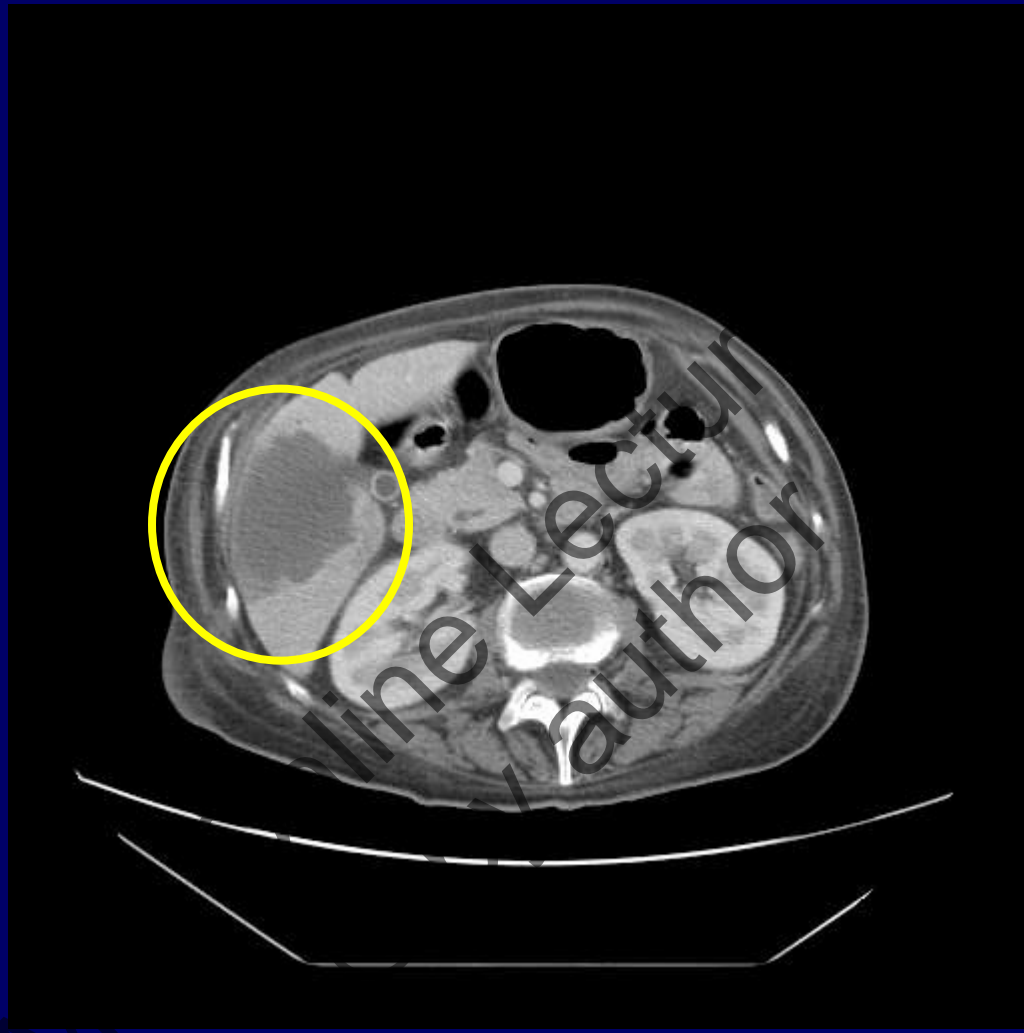
Clinical case 1

- **Aug 2005 : AML**
- **29/08 Ist treatment: Fludarabine, ARA-C, Idarubicine → fever in neutropenic phase, OK with antibiotics**
- **26/09 disease progression → 05/10 II treatment course (My-MEC: (mitoxantrone, etoposide, cytarabine, Myelotarg))**

- **17/10 galactomannan positive**
- **Starts vorico 6 mg/kg bid → 4 mg/kg/bid e.v.**
- **CT scan**



- **22/10** Fever subsides, clinically better, **GM still positive**, no evidence of other IA-related syndromes
- **Search for something else?**
- **5/11 abdomen CT scan**



ultrasonography-assisted needle aspirate

Clinical case 2

- Male, DOB 03/07/1981
- 04/2004 ALL diagnosis
- 25/10/05 HSCT from HLA-identical sibling
- Whole body CT scan (pre-transplant) negative

Day 13: fever persists, still neutropenic, starts ABLC (Abelcet)

Clinical worsening, mental confusion

Total bilirubin 6

aGVHD II > III

Skin and liver (ALT 320, ALP 712)

E. Coli (susceptible to pip-tazo) bacteremia

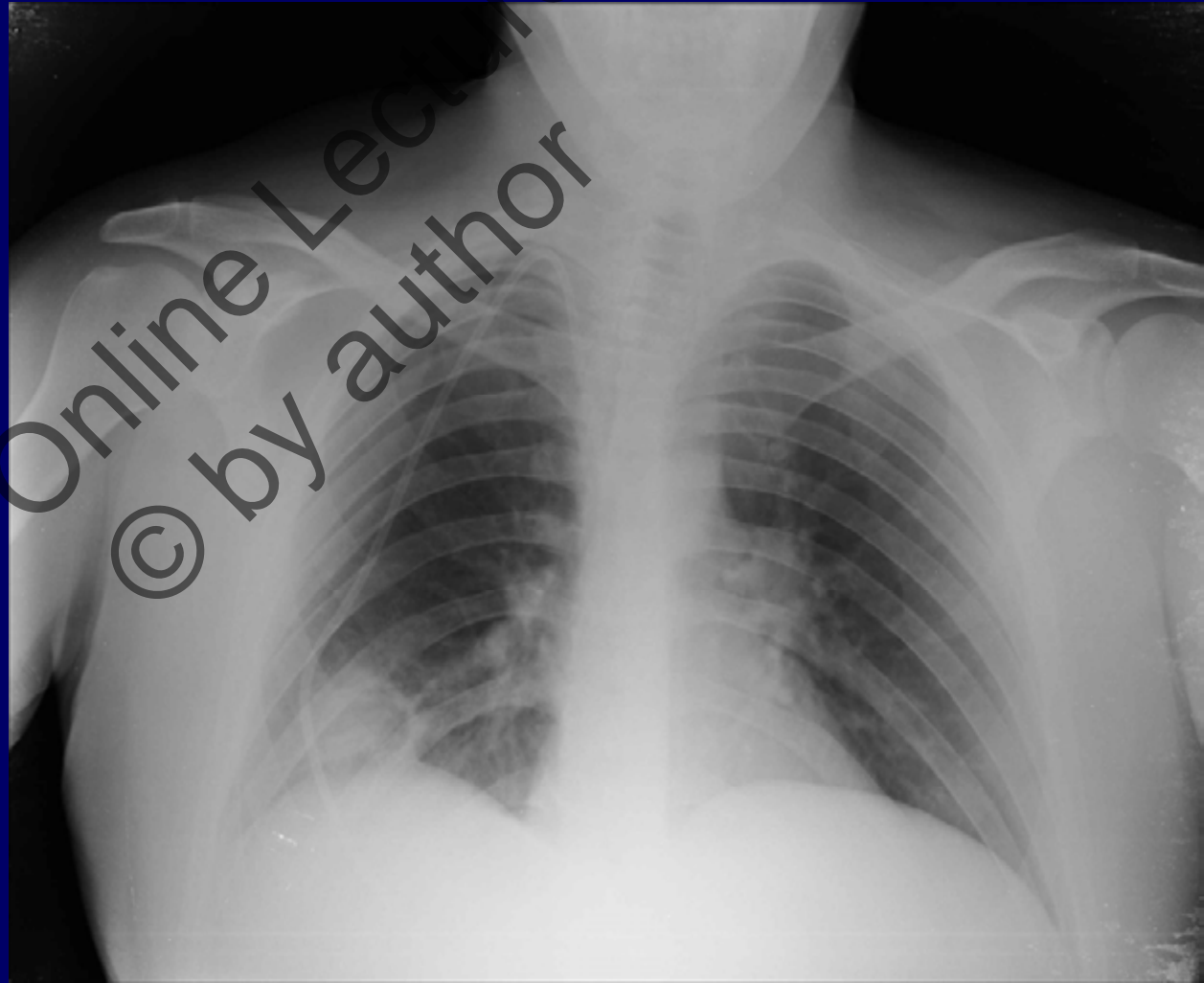
D 17 GM 2,6

Chest x-Rays

d 24 GM 0,8

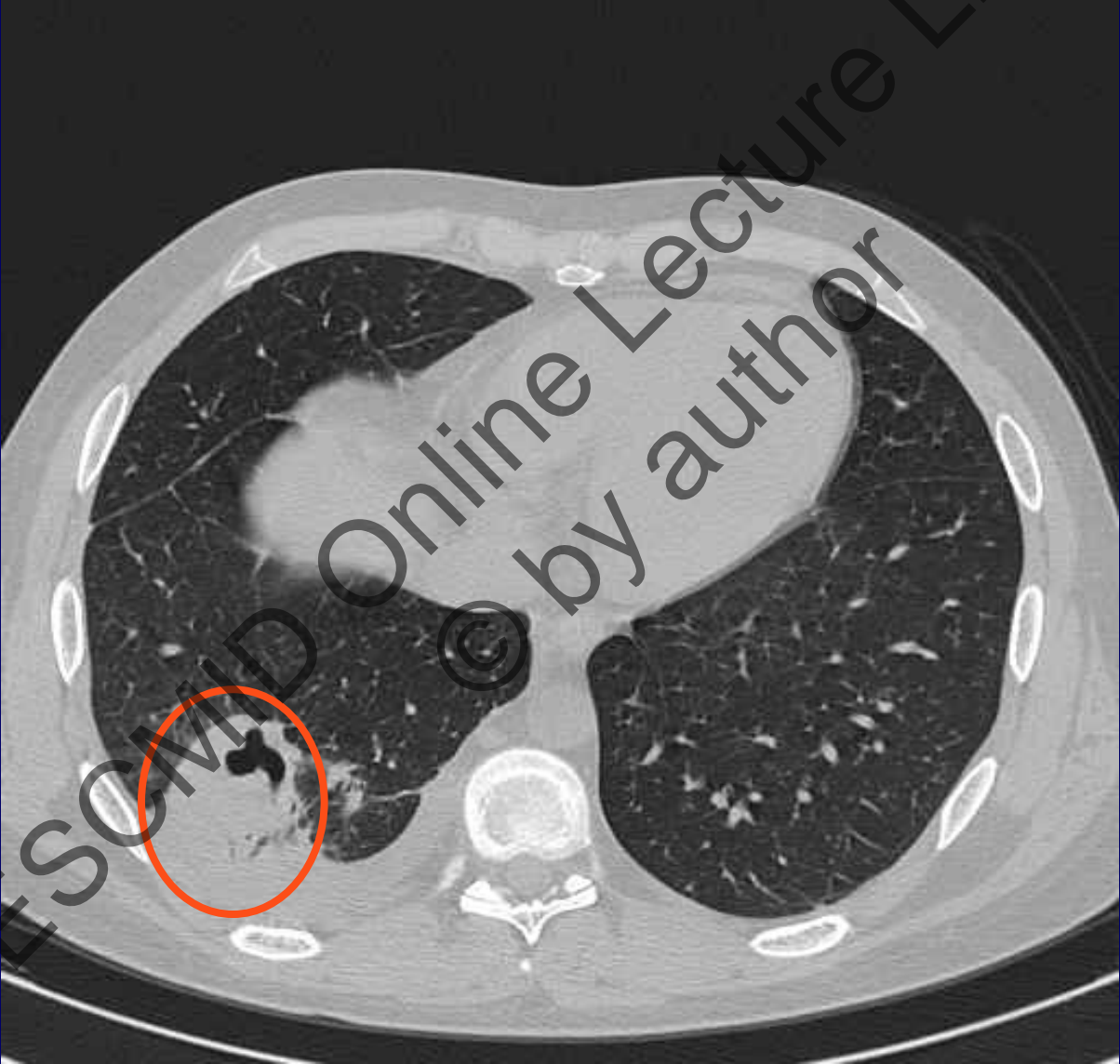
d 31 GM 2,0

d 30 caspofungin



aGVHD III: Cys, metilprednisolone

25/11/05 (d 31) HRCT

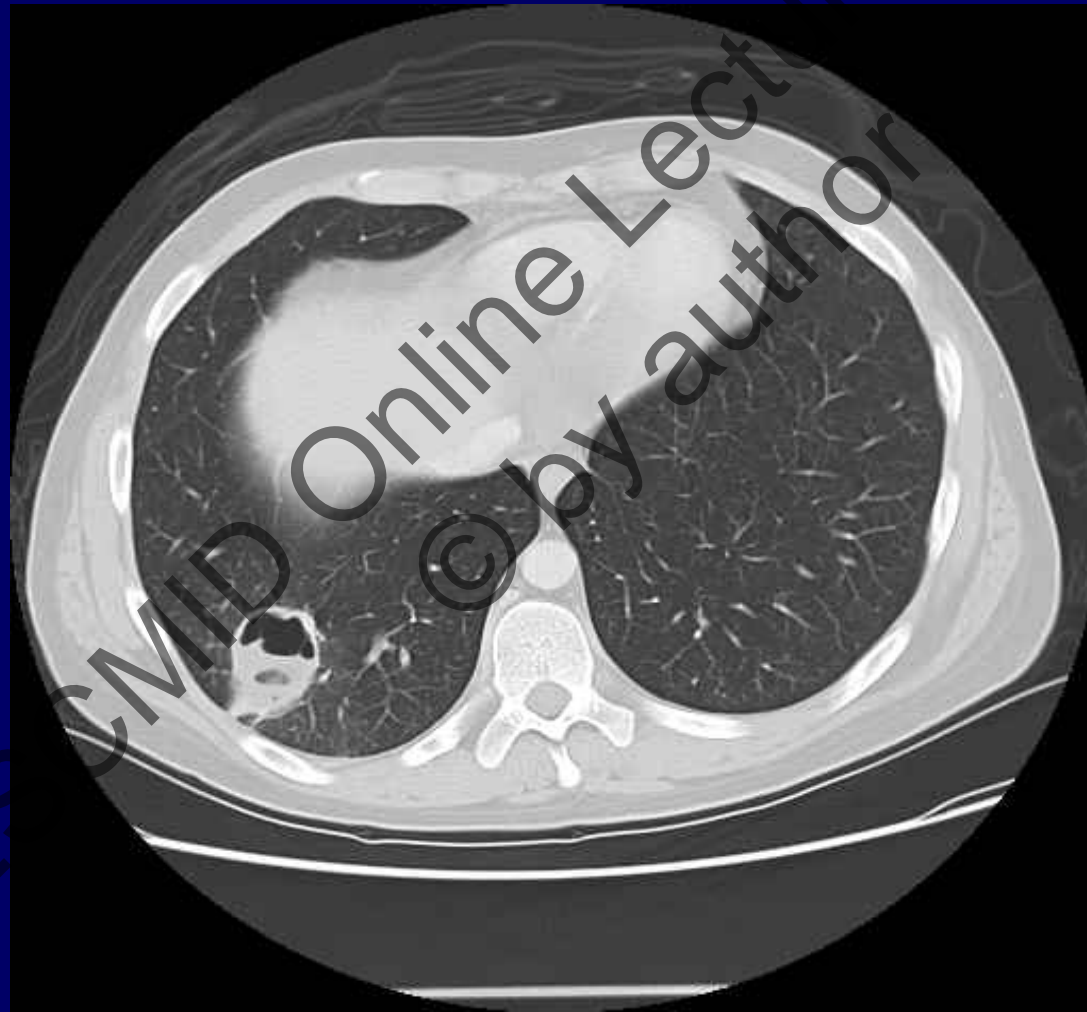

+45 GM 2,8

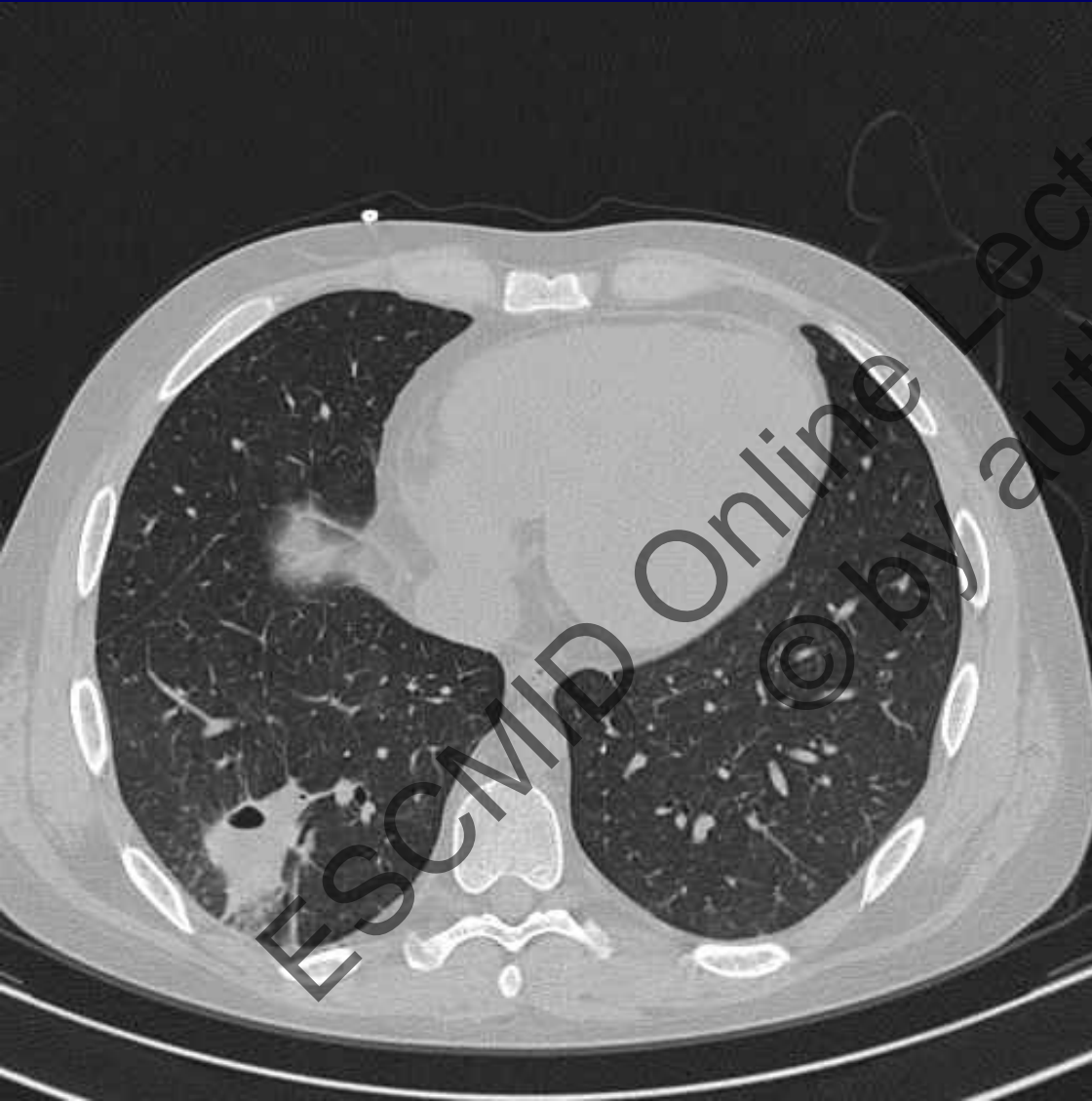
Caspofungin + LAMB (Ambisome) d44

10/12/05 CT scan

d47



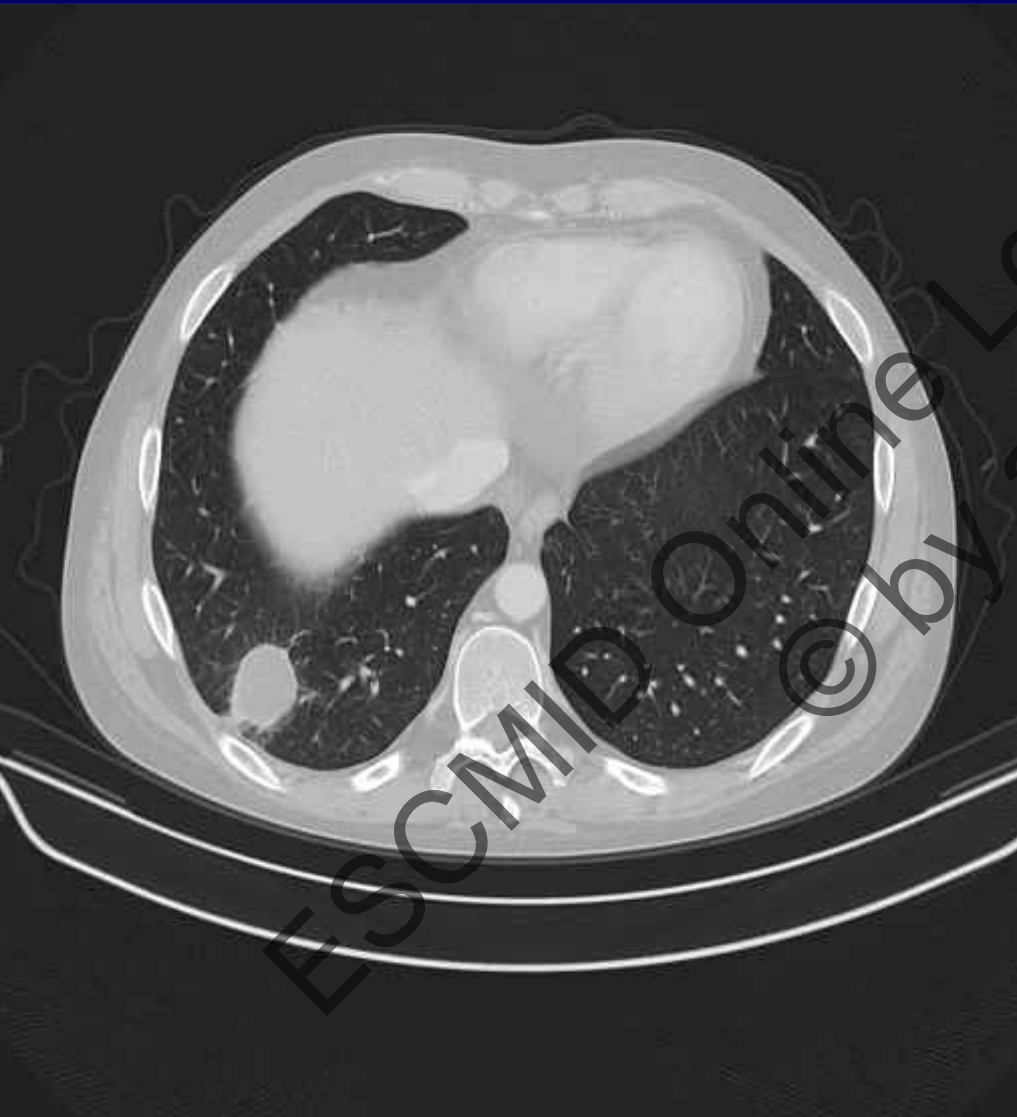
Two months after BMT



- d63 GM 1,7
- Improvement of GVHD liver and GI
- Starts Voriconazole d 64

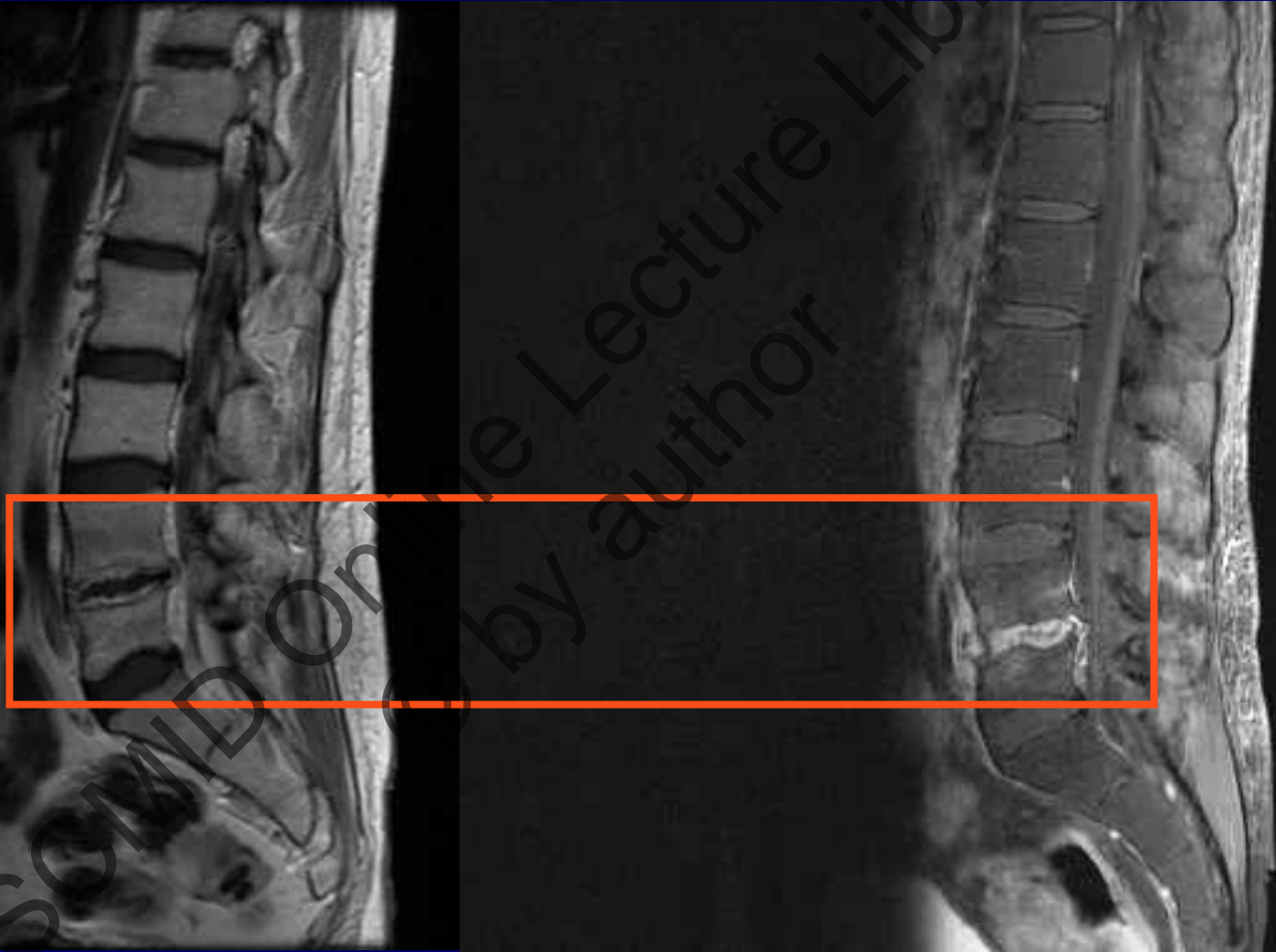
HRTC d 65

Three months after BMT



- D 94 GM 1,5
- Still in Voriconazole

26/09/06 Lumbar spine MRI d 340



L4-L5 spondylodiskitis