

ESCMID Postgraduate  
Technical Workshop

**Parasitic Infections of  
the Arabian Peninsula –  
a Theoretical  
and Practical Update**



**Al Ain, United Arab Emirates  
17 – 19 March 2016**



**C a s e s**

**Eskild Petersen, MD**

**Adjunct Professor of Tropical Medicine**

**Institute of Clinical Medicine**

**Aarhus University, Denmark**

**&**

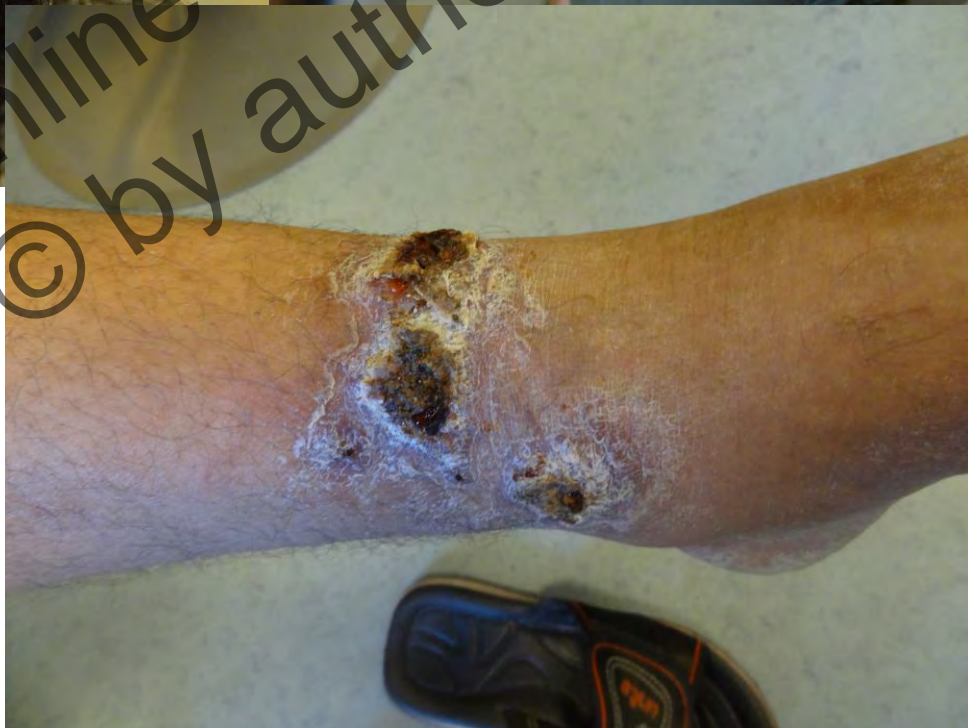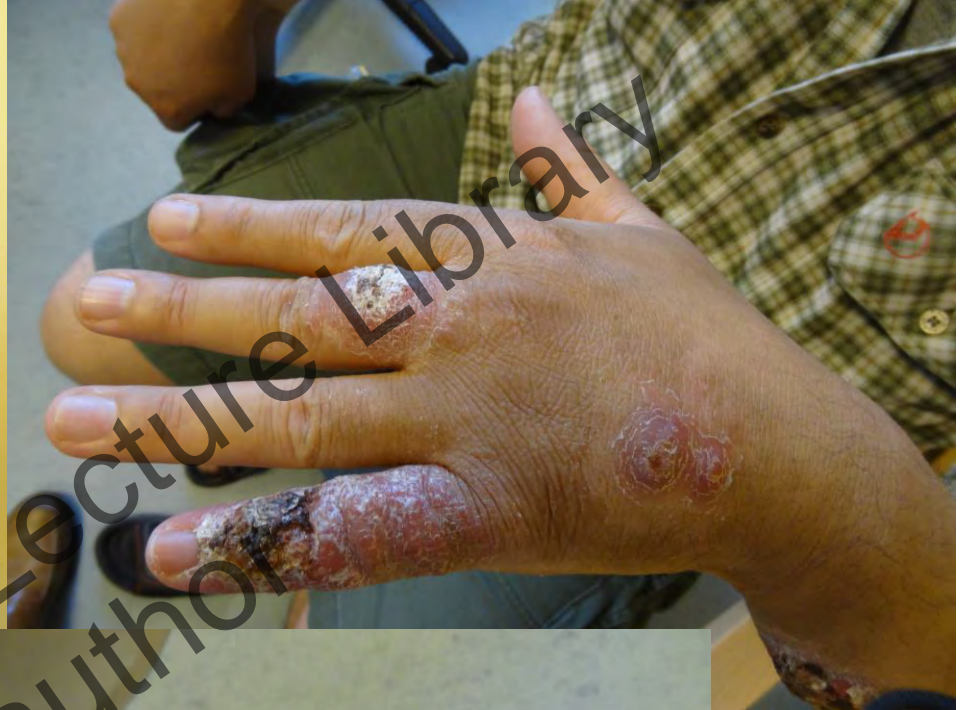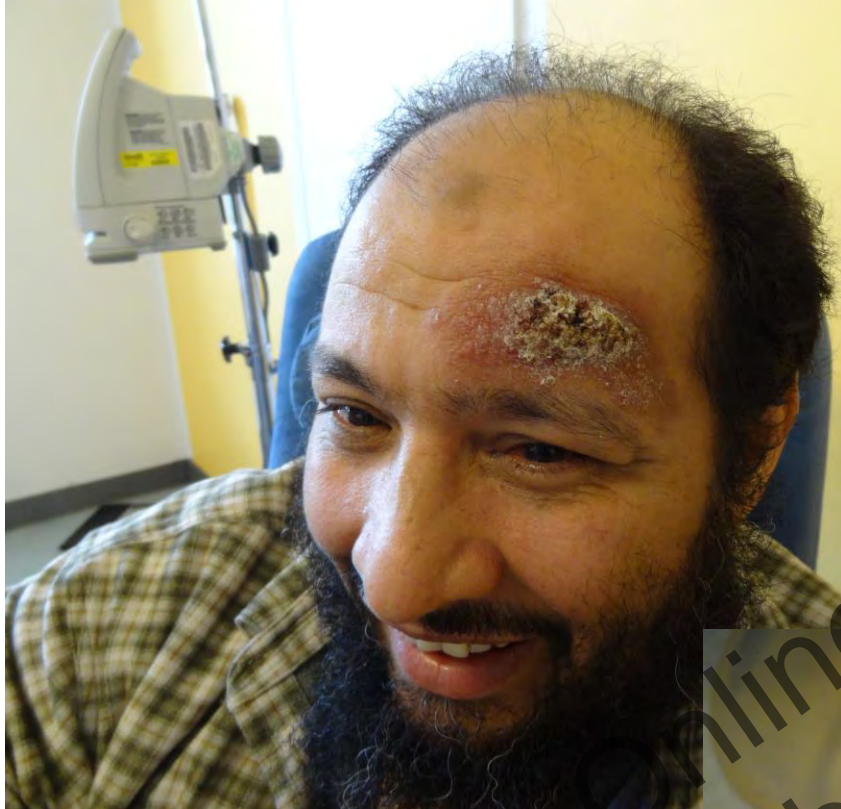**Senior Consultant**

**Department of Infectious Diseases**

**The Royal Hospital**

**Muscat**

**Sultanate of Oman**



Volunteer aid-worker  
Syrian refugee camps  
Southern Turkey



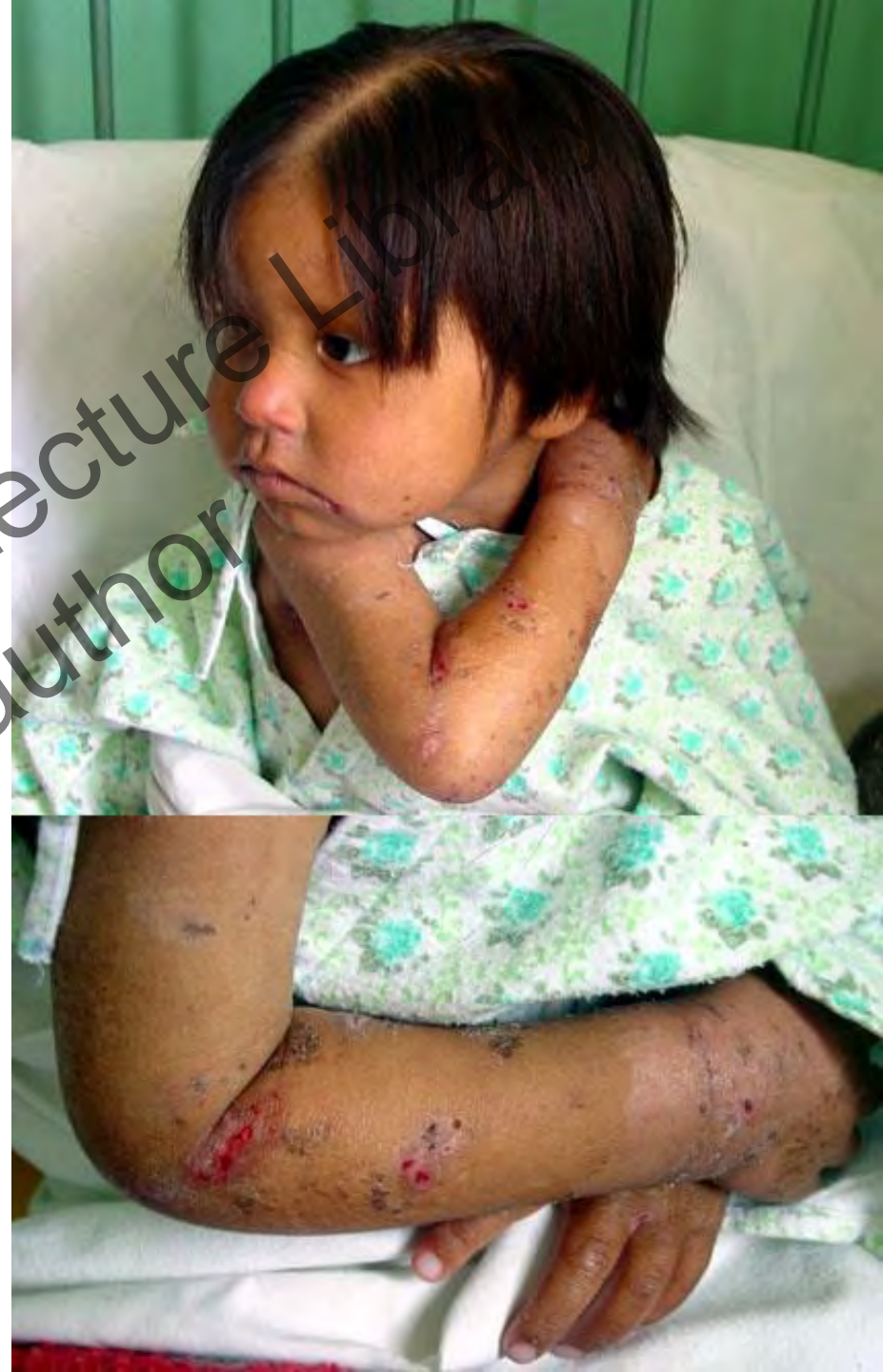**23 months old child adopted from Peru.**

**Skin rash with sores and apparent**

**itching**

**No fever**

**Scabies**



# Relapsing Cutaneous Leishmaniasis in a Patient Treated with Humira

<sup>1</sup>Erik Otte, <sup>1</sup>Mikael Christiansen and <sup>1,2</sup>Eskild Petersen

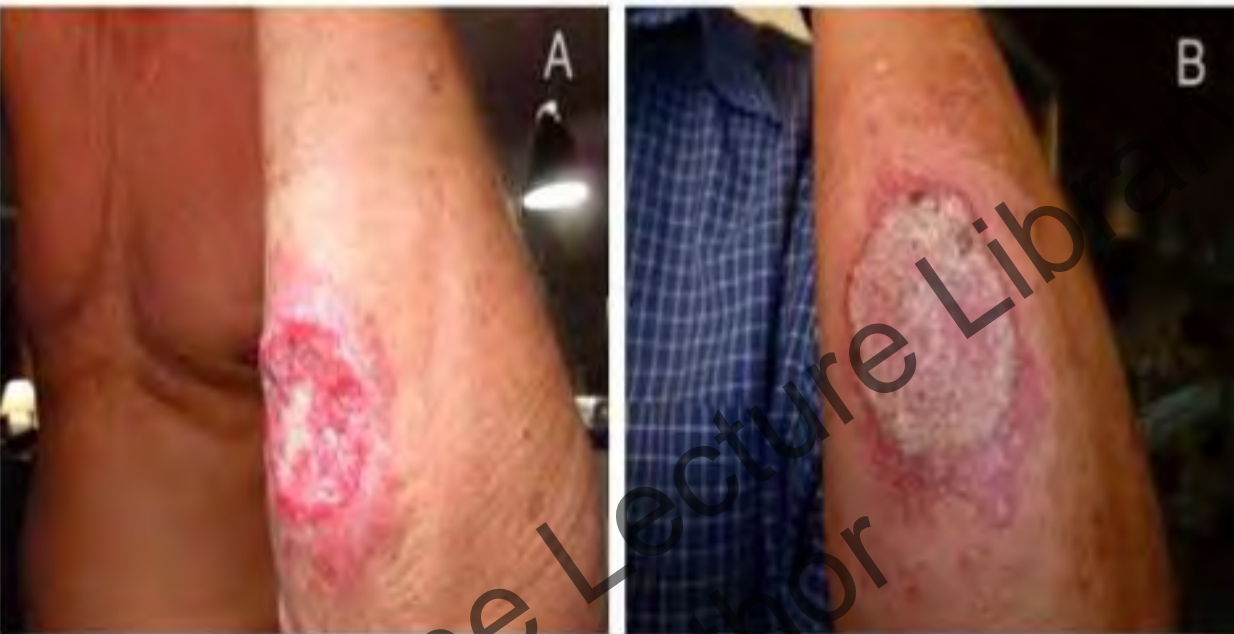


Fig. 1. Lesion before (A) and after miltefosin treatment (B)

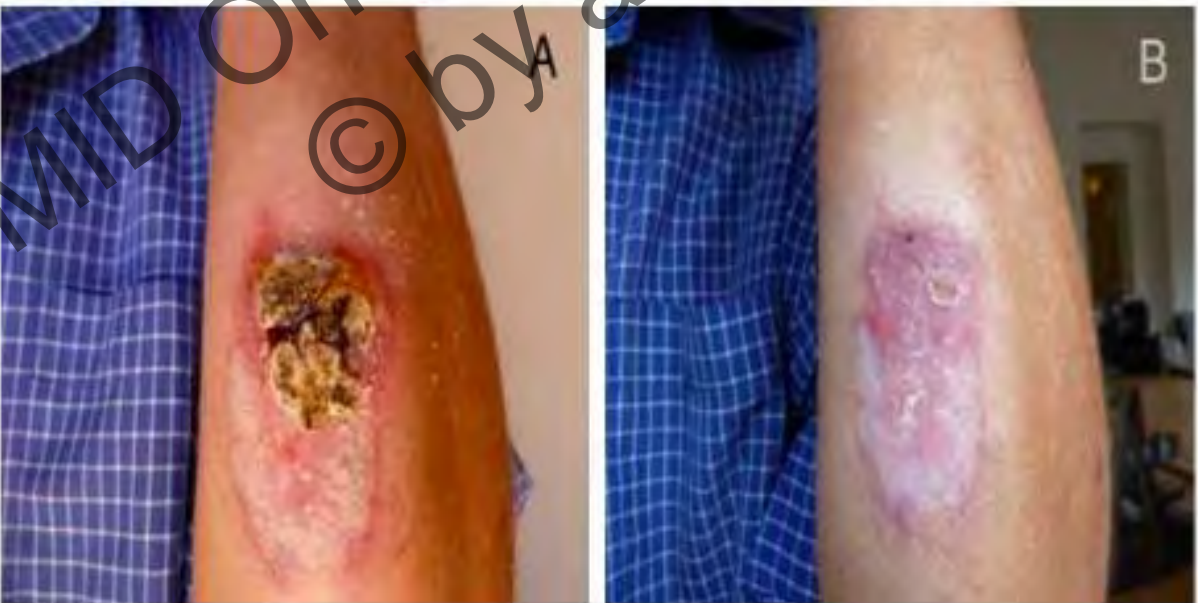

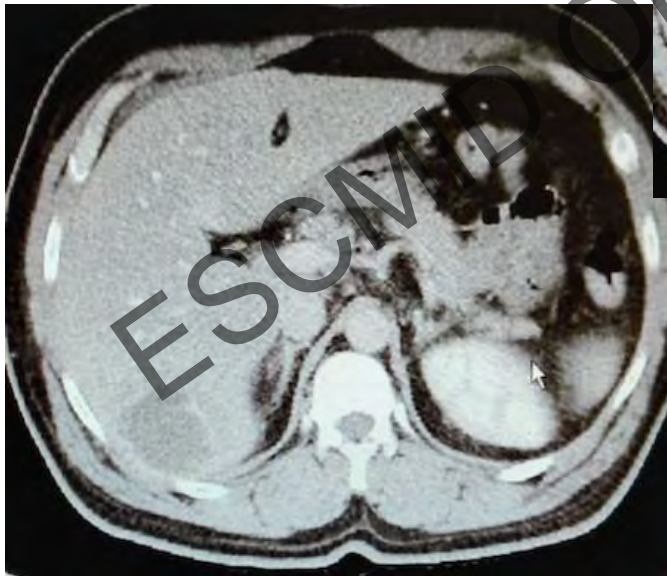
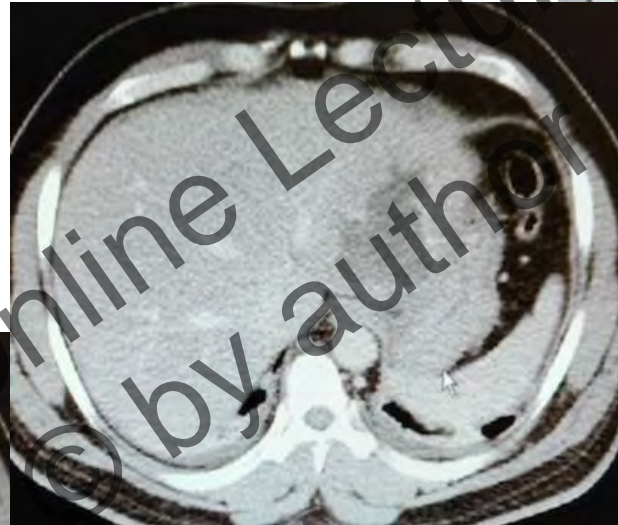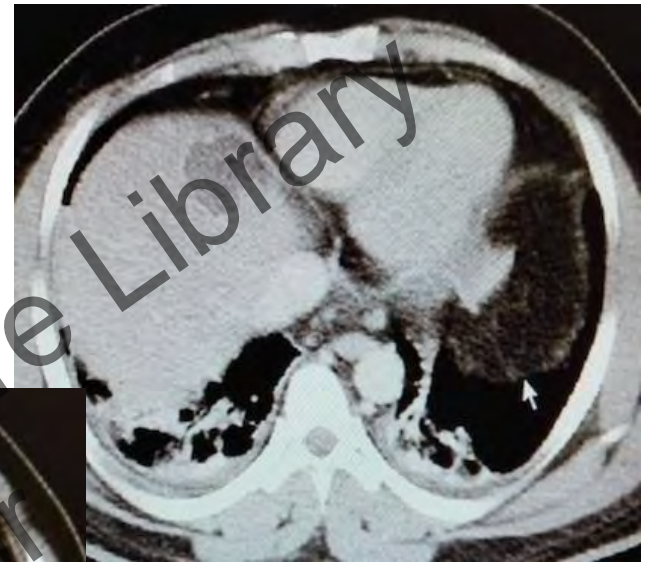Fig. 2. Lesion before (A) and after second l-AmB treatment (B)



33 year old Omani male

2 weeks stomach pain, no diarrhoea

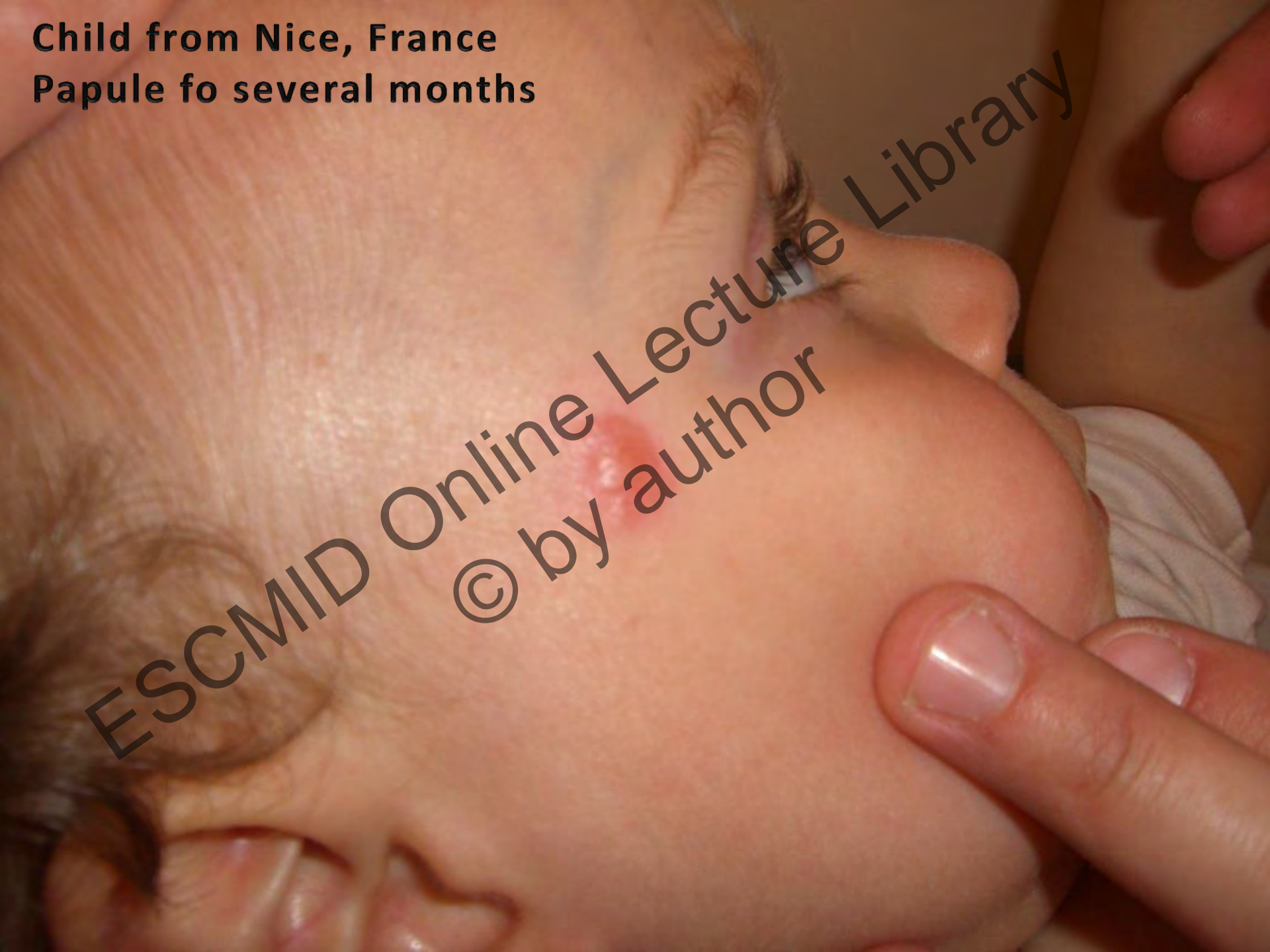Icteric, bilirubin 180



*E. histolytica* titer 1:8000

(cut off 1:32)

**Child from Nice, France**  
**Papule fo several months**



ESCMID Online Lecture Library  
© by author