

## Case 3

### Clinical imported fever cases

ESCMID Workshop, Thessaloniki, March 2016

Nick Beeching

Senior Lecturer in Infectious Diseases

Liverpool School of Tropical Medicine

NIHR Health Protection Research Unit in  
Emerging and Zoonotic Infections, Liverpool



### 28 year old woman

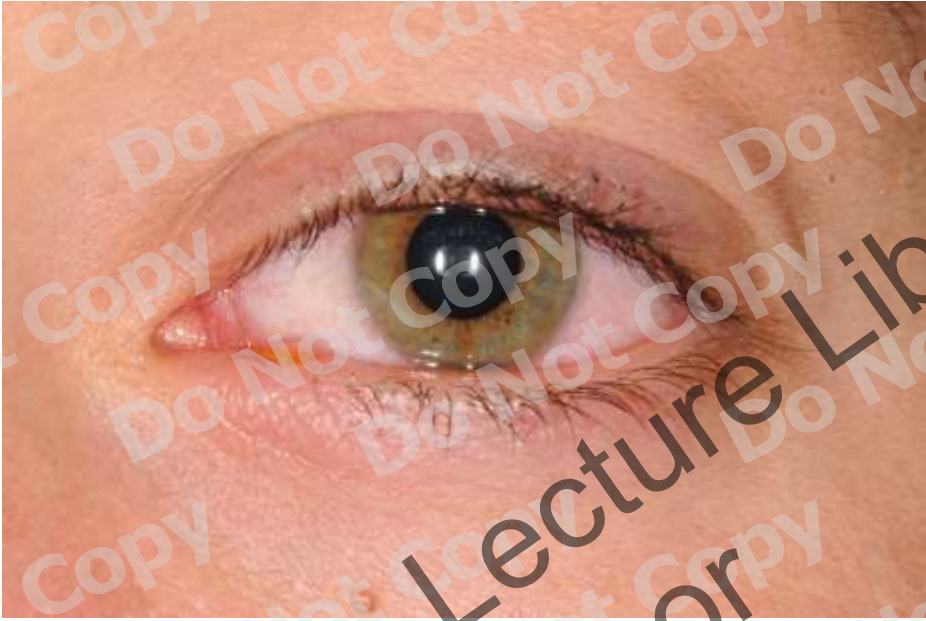- Referred by family doctor Feb 2016
- Two week holiday in Dominican Republic
- Returned 5 days ago
  
- Now 4 days
  - Fever
  - Myalgia
  - Painful eyes

## History

- Took malaria prophylaxis
- Also on oral contraceptive pill
- Past yellow fever immunization
- Mild diarrhoea on days 3-4 of holiday
- Boyfriend who accompanied – no symptoms

## On examination

- Well
- Temp 37.2
- Red eye
- No rash
- No lymphadenopathy



Question 1. What is the most likely diagnosis?

1. Adenovirus conjunctivitis
2. Chikungunya
3. Dengue
4. Leptospirosis
5. Zika
6. Something else

Question 1. What is the most likely diagnosis?

1. Adenovirus conjunctivitis
2. Chikungunya
3. Dengue
4. Leptospirosis
5. Zika
6. Something else

Immediate laboratory tests

- Haemoglobin 127 g/L (12.7 g/dL)
- White cells  $5.6 \times 10^9/L$
- Platelets  $286 \times 10^6/L$
- Liver function tests normal
- Biochemistry normal

Comparison of symptoms for dengue fever, chikungunya, and Zika.  
*Clinique comparée de la dengue, du chikungunya et du Zika.*

Symptoms	Dengue	Chikungunya	Zika
Fever	++++	+++	+++
Myalgia/arthralgia	+++	++++	++
Edema of extremities	0	0	++
Maculopapular rash	++	++	+++
Retro-orbital pain	++	+	++
Conjunctivitis	0	+	+++
Lymphadenopathies	++	++	+
Hepatomegaly	0	+++	0
Leukopenia/thrombopenia	+++	+++	0
Hemorrhage	+	0	0

Ioos S *et al.* Current Zika virus epidemiology and recent epidemics. *Med Mal Infect.* 2014 Jul;44(7):302-7. <http://dx.doi.org/10.1016/j.medmal.2014.04.008>

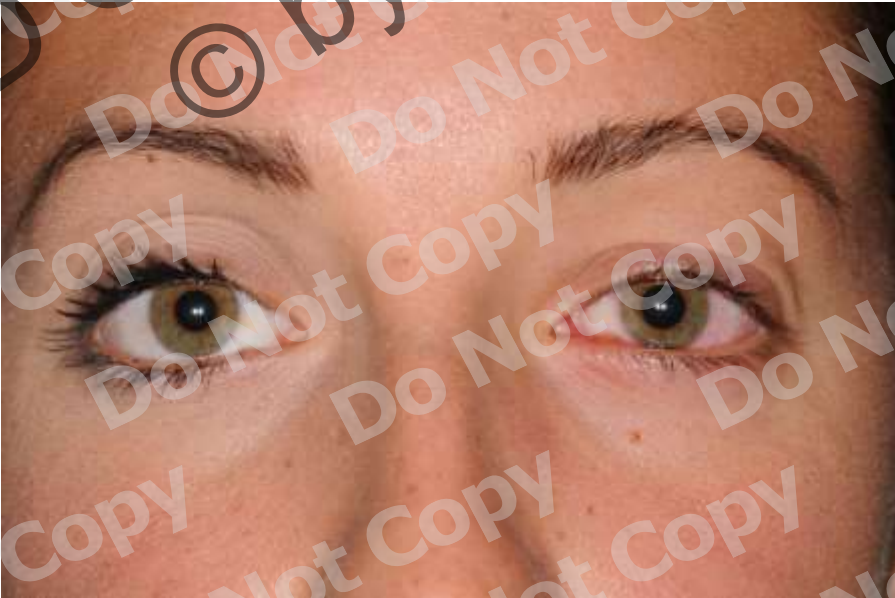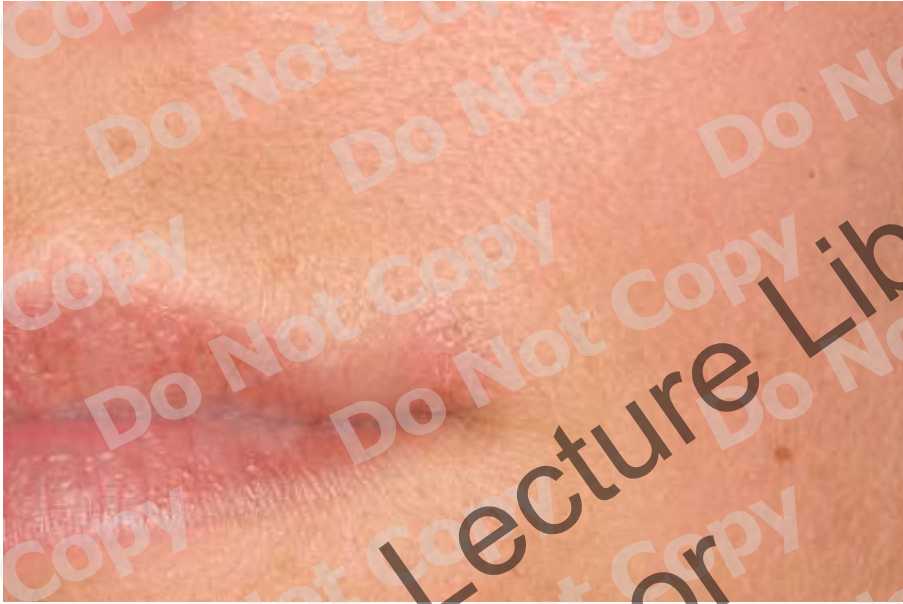
Q2. What test would be most useful to diagnose Zika?

1. Electron microscopy of conjunctival smear
2. PCR on blood for ZIKV
3. Special virus culture of blood for ZIKV
4. Western blot
5. Serology for ZIKV

Q2. What test would be most useful to diagnose Zika?

1. Electron microscopy of conjunctival smear
2. PCR on blood for ZIKV
3. Special virus culture of blood for ZIKV
4. Western blot
5. Serology for ZIKV

Further examination



© by author

## Outcome

- ZIKV PCR negative
- Serology positive flavivirus IgG (NB past yellow fever immunization)
- Ophthalmic examination normal – no herpetic ulcers
- Diagnosis uncertain ? Mild herpetic or other unilateral conjunctivitis

Q3. She wants to know if her boyfriend has been infected with ZIKV– what do you advise?

1. Nothing - wait and see if he gets a rash
2. Nothing will help diagnose his infection – advise using condoms for 1 month
3. Request PCR on his blood for ZIKV
4. Send paired serology from him to detect ZIKV IgM/IgG
5. Something else



Q3. She wants to know if her boyfriend has been infected with ZIKV— what do you advise?

1. Nothing - wait and see if he gets a rash
2. Nothing will help diagnose his infection – advise using condoms for 1 month
3. Request PCR on his blood for ZIKV
4. Send paired serology from him to detect ZIKV IgM/IgG
5. Something else

Countries that pregnant women should avoid



\*Other American Samoa, Cape Verde and Tonga should also be avoided.

New York Times & LSTM (The New York Times) | Sources: Centers for Disease Control and Prevention | Photo Attribution: iStock.com

## Summary

- Not all infections from S America/Caribbean are Zika
- Symptomatic Zika more likely to have rash and conjunctivitis than DEN/CHIK but overlap
- In endemic areas for 2 or 3 of these viruses, lack of white cell changes may help differentiate ZIK from DEN/CHIK
- Lack of good serological tests for ZIK

Ahmad SY *et al.* Zika virus: management of infection and risk.  
*BMJ* Feb 26; 352: i1062 doi:10.1136/bmj.i1062