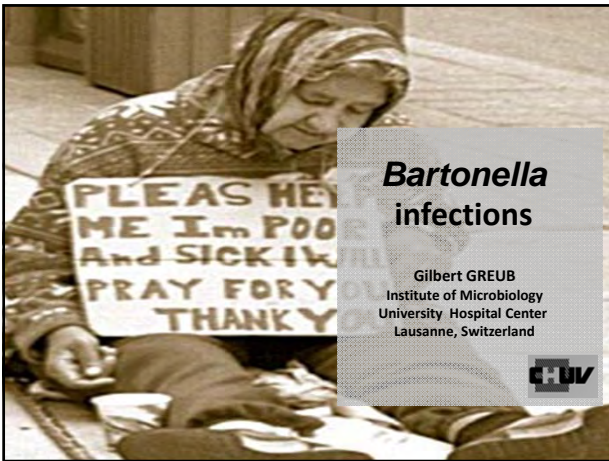



### Bartonella

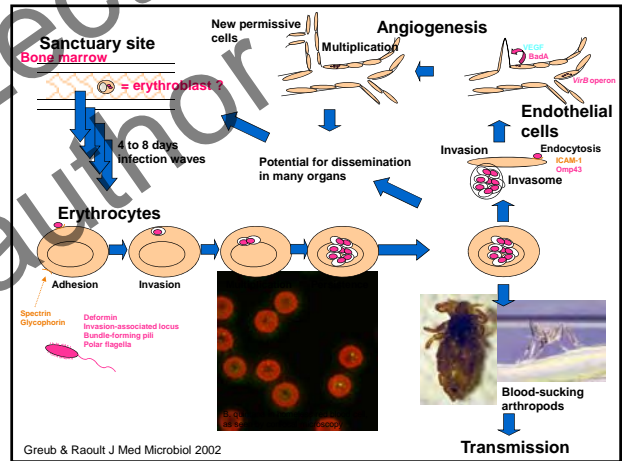
- Gram negative rod
- Oxidase negative
- aerobic (5% CO<sub>2</sub>)
- GC content about 40%
- Growth on blood agar

### Bartonella

Alpha-2 proteobacteria

Related to:

- Brucella*
- Agrobacterium tumefaciens*
- Bosea*
- Afipia*



### Bartonella

Animal = reservoir of many *Bartonella* species

- in cats: retinitis, endocarditis, stomatitis
- in dogs: endocarditis, granulomatous hepatitis
- in horses: osteoarthritis
- in pigs, koalas, marsupials, sea mammals, ...


14 species may infect humans

- B. vinsonii* subsp. *vinsonii*
- B. vinsonii* subsp. *arupensis*
- B. vinsonii* subsp. *berkhoffi*
- B. washoensis*
- B. quintana*
- B. henselae*
- B. alsatica*
- B. doshiae*
- B. taylorii*
- B. grahamii*
- B. tribocorum*
- B. elizabethae*
- B. bacilliformis*
- B. clarridgeiae*
- B. weissii*
- B. birtlesii*
- Brucella abortus*

0.1

**Bartonella**


*B. bacilliformis* Carrion disease  
verruaga peruana



Lutzomyia

**Bartonella**


*B. bacilliformis* Carrion disease  
verruaga peruana Oroya fever



Hemolytic anemia + fever

**Bartonella**


*B. bacilliformis* Carrion disease  
*B. quintana* Trench fever



1914-1918  
Quintan fieber - Trench fever

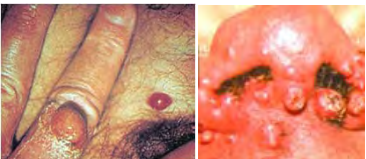
**Bartonella**

*B. bacilliformis* Carrion disease  
*B. quintana* Trench fever  
Chronic bacteremia




**Bartonella**

*B. bacilliformis* Carrion disease  
*B. quintana* Trench fever  
Chronic bacteremia  
Bacillary angiomatosis  
Hepatic peliosis





**Bartonella**







*B. bacilliformis* Carrion disease  
*B. quintana* Trench fever  
Chronic bacteremia  
Bacillary angiomatosis  
Hepatic peliosis  
*B. henselae* Cat-scratch disease




**Bartonella**

<b><i>B. bacilliformis</i></b>	Carrion disease
<b><i>B. quintana</i></b>	Trench fever
	Chronic bacteremia
	Bacillary angiomatosis
	Hepatic peliosis
<b><i>B. henselae</i></b>	Cat-scratch disease
	Endocarditis

<b><i>B. bacilliformis</i></b>	<b><i>B. quintana</i></b>	<b><i>B. henselae</i></b>
<b>Carrion disease</b> - verruaga peruana - fièvre d'Oroya	<b>Fièvre des tranchées</b>	<b>Maladie des griffes de chat</b>
		
	<b>Angiomatose bacillaire</b>	<b>Endocardite</b>
		



**Risk factors**

<b><i>B. henselae</i></b>	
Contact with a cat	Cat-scratch disease
+ valvular disease	Endocarditis
+ HIV infection	Bacillary angiomatosis




Boillat & Greub, Rev Med Suisse 2008




**Risk factors**

<b><i>B. henselae</i></b>	
Contact with a cat	Cat-scratch disease
+ valvular disease	Endocarditis
+ HIV infection	Bacillary angiomatosis
<b><i>B. quintana</i></b>	
Homeless, OH	Chronic bacteremia
	Endocarditis
+ HIV infection	Bacillary angiomatosis




Boillat & Greub, Rev Med Suisse 2008



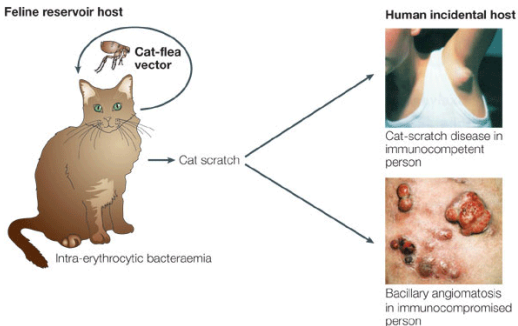
**Risk factors**

<b><i>B. henselae</i></b>	
Contact with a cat	Cat-scratch disease
+ valvular disease	Endocarditis
+ HIV infection	Bacillary angiomatosis
<b><i>B. quintana</i></b>	
Homeless, OH	Chronic bacteremia
	Endocarditis
+ HIV infection	Bacillary angiomatosis
<b><i>B. bacilliformis</i></b>	
Travellers (Peru, Bolivia, Ecuador)	Oroya fever
Autochthonous (Peru, Bolivia, Ecuador)	Verruaga peruana

Boillat & Greub, Rev Med Suisse 2008



**Cat-scratch disease**



Feline reservoir host

Human incidental host


Cat-scratch

Cat-scratch disease in immunocompetent person

Bacillary angiomatosis in immunocompromised person

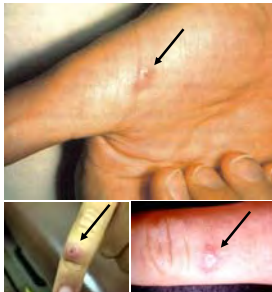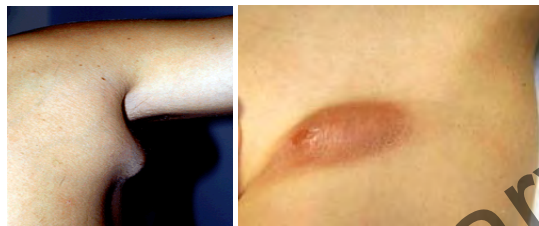Intra-erythrocytic bacteraemia

Dehio et al. Nat Microbiol Rev

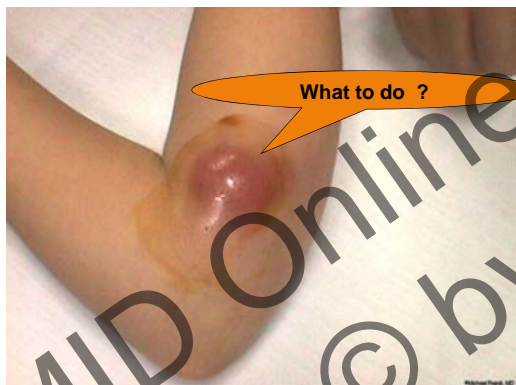

**Inoculation lesions**

- present in 60% of cases
- appear 3 to 10 days after inoculation
- 10 days before lymphadenopathy
- persist during 1 to 3 weeks


**Cat-scratch disease**

- Isolated adenopathy
- Persist during 2 to 6 months
- Generally, spontaneous resolution
- Fever, myalgia, asthenia


**Oculo-glandular sy. = Parinaud syndrome**

- following a conjunctival inoculation:
  - pre-auricular adenopathy
  - conjunctivitis and/or retinitis

**Complications of cat-scratch disease**

- suppuration (10-15%)
- hepatosplenic lesions
- neurological lesions
- arthritis / osteomyelitis
- endocarditis
- ...

**Diagnosis****Molecular diagnosis (PCR)**

- cat-scratch disease, endocarditis, ...

**Serology**

- endocarditis (very high titres)
- microimmunofluorescence + W-blot

(poor sensitivity for bacillary angiomatosis)

**Histology + immunohistology****Culture**
**Diagnosis (difficult to grow)****Cell culture >> axenic culture****Endothelial cells + centrifugation**

Sensitivity 10x better than blood agar

p<0.001 from valves

p=0.045 from blood

Fournier et al. J clin Microbiol 2002

**Better sensitivity when:**

- Subculture blood cultures bottles on agar after 7 days
- Congelation / saponin

Attention: low CO<sub>2</sub> production

(undetected by automated systems)

## Diagnosis (difficult to grow)

### Shell vial

#### Practically:

- human endothelial cells (ECV304)  
in RPMI 15% fetal calf serum 2% glutamine
- read-out: Gimenez staining, immunofluorescence  
on day 15 (30/45 if negative)

Gouriet et al. J Clin Microbiol 2005

#### - Sensitivity: serology >> PCR >> culture

89.5% (39/48)	47.6% (10/21)	25.0% ( 9/36)	on blood
97.7% (44/45)	37.5% (18/48)		on valve

Houpikian et al. Medicine 2002  
Fournier et al. CDLI 2002



## Treatment

### Cat scratch disease

Treatif major adenopathy or in case of immunosuppression  
- azithromycin 500 mg/day J1; then 250 mg/day for 2-5 days

If retinitis or neurological involment:

- doxy 2x100 mg/day + rifampicine 2x 300 mg/day for 4-6 weeks

### Bacteriemia / endocarditis

- doxy 2x 100 mg/day for 4-6 weeks  
+ gentamycin 3mg/kg for 2 weeks

### Bacillary angiomatosis

- Erythromycin 4 x 500 mg/day or doxy 2x100 mg/d for 3 months

Boillat & Greub. Rev Med Suisse 2008; Rolain et al. Ant. Agents Chemother 2005



## Conclusions

No need of antibiotic for uncomplicated  
cat-scratch disease

Include bartonella in the differential diagnosis  
of blood-culture negative endocarditis

Bacillary angiomatosis should be part of  
differential diagnosis in HIV-infected patients  
with low CD4 count and fever

Consider Carrion disease in a traveller returning  
from Andean with hemolytic anaemia



## Recommended readings:

### Diagnosis and treatment

Boillat & Greub  
Rev Med Suisse romande 2008;4:901-907

Greub & Raoult  
Chapter 2 in « Emerging Infectious Diseases » Kluwer 2003

Rolain et al.  
Antimicrob Ag Chemother 2004

### Pathogenesis

Greub & Raoult  
J Med Microbiology 2002.

Riess & al.  
J Exp Med 2004

Dehio et al  
J Cell Sci 1997

Vayssier-Taussat et al.  
PLOS pathogens 2010

